



# Evidence of occurrence of intersex in Indo-Pacific sergeant, *Abudefduf vaigiensis*

N. Rajesh\*, P. P. Suresh Babu, M. T. Shilta, A. Anuraj, K. K. Anikuttan, P. Shelton and Bobby Ignatius

ICAR-Central Marine Fisheries Research Institute, Kochi- 682 018, Kerala, India.

\*Correspondence email: [rajeshcmfri2020@gmail.com](mailto:rajeshcmfri2020@gmail.com)

ORCID: <https://orcid.org/0009-0005-2022-556X>

Received: 17 Apr 2025 Revised: 11 Jun 2025

Accepted: 12 Jun 2025 Published: 17 Jun 2025

## Original Article

### Abstract

The gonadal morphology and reproductive strategy of *Abudefduf vaigiensis*, a reef-associated damselfish, collected from Maraikayar Pattinam, Mandapam, Tamil Nadu, India, was investigated. A total of 120 specimens were examined through gross anatomical and histological analyses to assess gonadal structure and sexual characteristics. Among the 110 mature fish (70 males and 40 females; 10–15 cm TL), 4 individuals (10–12 cm TL) exhibited intersex gonads; 10 were unsexed. Typical gonochoristic features were recorded in both sexes in many of the cases (92%), whilst other fishes were found with immature gonads. Mature testes appeared bilobed and asymmetrical, with histological sections revealing active spermatogenesis and well-defined seminiferous lobules. Ovaries exhibited asynchronous development, containing vitellogenic, lipid vesicles, and perinuclear oocytes, suggesting batch spawning potential. Intersex gonads displaying testicular tissue distributed in the developing ovarian lobe were identified and confirmed histologically. This indicates the first histological evidence of intersex in this species. These findings challenge the previously held assumption of strict gonochorism in *Abudefduf* spp. and highlight the need for broader temporal and spatial sampling to understand the ecological and captive breeding implications of reproductive plasticity in this taxon. The results indicated the presence of either a sequential hermaphroditism or potential endocrine disruption in the species.

**Keywords:** Sergeant major, hermaphrodite, endocrine disruption, intersex, reproductive strategy, histology

### Introduction

Reproductive biology is fundamental to effective captive breeding and aquaculture development. Understanding reproductive traits enables the optimisation of broodstock management, hormone-induced spawning, and controlled

breeding, thereby improving seed production and stock enhancement (Mylonas *et al.*, 2010). Additionally, it provides insights into the effects of environmental stressors on reproductive success (Schreck, 2010). The sexual development of teleost fishes reveals their wide-ranging and flexible breeding strategies. Many teleost fishes are gonochorists, meaning they remain either male or female in their entire lives. However, other teleost species are hermaphroditic, producing both male and female gametes at some point in their life cycle (Devlin and Nagahama, 2002). Apart from these two strategies, intersex conditions have also been documented in fish species belonging to 17 families in several field survey studies (Bahamonde *et al.*, 2013).

Hermaphroditism is a reproductive strategy wherein individuals possess both male and female reproductive tissues; it occurs widely among teleosts. It can be simultaneous or sequential, with the latter including protogyny, protandry, and bidirectional sex change, often influenced by environmental or social factors (Sadovy and Shapiro, 1987; Warner, 1984). This strategy enhances reproductive flexibility and fitness, particularly in species with complex social structures or limited mate availability (Munday *et al.*, 2006). Intersex is defined as the simultaneous presence of male and female gonadal tissue in a gonochoristic species (Tyler and Jobling, 2008), either simultaneously (ovotestis) or in transitional stages during sex reversal.

Intersex condition can occur naturally as part of the life history in hermaphroditic species or be induced by environmental factors, especially endocrine-disrupting chemicals (EDCs) in aquatic systems. Endocrine disruption in fish refers to the interference of normal hormonal processes by exogenous substances, often leading to altered development, physiology, behaviour, and reproduction. These substances, known as endocrine-disrupting chemicals (EDCs), include natural

hormones, synthetic estrogens, industrial compounds, and pharmaceuticals introduced into aquatic environments.

Ornamental fish keeping is a rapidly expanding industry driven by the demand for newer species with diverse sizes and striking colour patterns. Among marine ornamental fishes, the family Pomacentridae is particularly valued for its small body size, bright colouration, and adaptability to captive conditions. Damselfishes (Pomacentridae), including the genus *Abudefduf*, one of the youngest clades within the family, are both ecologically significant and commercially important in the ornamental fish trade, where Pomacentridae is the most dominant family (Wabnitz *et al.*, 2003; Allen, 1975; Randall, 2005). While hermaphroditism is well documented in families such as *Serranidae* and *Labridae*, *Abudefduf* species belonging to the Pomacentridae family have been considered gonochoristic, with fixed sexes throughout life. *Abudefduf vaigiensis*, commonly known as the Indo-Pacific sergeant major fish species, is one of the important marine ornamental fish species in the genus, which contributes significantly to the total marine ornamental fish trade in India. In *A. vaigiensis*, males (9.44 cm) attain length at first maturity shorter than females (10.32 cm) (Canini and Metello, 2024). The present study provides the first evidence of intersex in *A. vaigiensis*, challenging the long-held assumption of strict gonochorism within the genus and opening new avenues for reproductive and aquaculture research.

## Material and methods

### Collection of samples

The fish samples for the present study were collected from Maraikayar Pattinam, Mandapam, Tamil Nadu, India, from October 2019 to September 2021. The representative specimen and the collection site are indicated in Fig. 1. A total of 120

samples collected from the site were transported to the laboratory in oxygenated packs. Morphometric indices such as length and weight of the samples were noted before aseptically removing the gonads for observation.

### Gross examination gonads

The fish were anesthetised using 0.01% clove oil in seawater (32 ppt) for 2 minutes. The anesthetised fish were aseptically dissected, and the gonads were removed. The morphology of the gonad was recorded using a digital camera (Nikon Coolpix P7100 digital camera, Japan). The middle portion of the gonads was excised and fixed in neutral buffered formalin for further histological evaluations

### Histology

Longitudinal ovarian sections were cut at a thickness of 5  $\mu$ m, then dewaxed and rehydrated through a graded ethanol series. The sections were stained with hematoxylin and eosin, and permanent slides were prepared according to the protocol described by Gabe (1976). Photomicrographs were taken using a Zeiss Axio Scope A1 compound microscope fitted with a Jenoptik ProgRes C3 digital camera to identify and confirm the stages of ovarian maturation.

## Results and discussion

Intersex in fish can arise from both natural biological processes and anthropogenic influences. Its increasing detection in wild fish populations highlights the importance of monitoring aquatic pollution and understanding endocrine disruption to protect aquatic ecosystems. In some teleosts, intersexuality is a normal physiological phase associated with sequential hermaphroditism. For instance, species like *Thalassoma bifasciatum* (bluehead wrasse) change sex as part of their




Fig. 1. a) A mature specimen of *Abudefduf vaigiensis*, b) location of sample collection

reproductive strategy (Sadovy and Shapiro, 1987). These transformations are typically well-regulated and linked to social and environmental cues. Intersex conditions have been increasingly reported in wild populations of gonochoristic fish (those with fixed sexes) and are often attributed to exposure to xenoestrogens and other EDCs, such as those found in agricultural runoff, sewage effluent, and industrial waste (Jobling *et al.*, 1998). These chemicals can mimic natural hormones and disrupt normal sexual differentiation and reproduction. Histologically, intersex gonads may show oocytes embedded within testicular tissue or vice versa. Severity is often graded based on the extent of opposite-sex tissue presence. In severe cases, full ovotestis formation can impair gametogenesis and fertility (Hinck *et al.*, 2009). The widespread occurrence of intersex in sentinel species such as *Cyprinidae* (e.g., roach, *Rutilus rutilus*) raises concerns about population-level impacts. Reduced reproductive output, skewed sex ratios, and compromised reproductive behaviour are potential consequences that can affect fish population dynamics and aquatic biodiversity (Kidd *et al.*, 2007).

Details of the morphometry, length at first maturity and sex ratio of the samples examined are given in Table 1. In the study,

Table 1. Details of the morphometry, length at first maturity and sex ratio of *A. vaigiensis*

Parameters	Male	Female	Intersex
Samples (No.)	70	40	4 (6 are undifferentiated)
Average length (cm)	12.52	12.21	12.30
Average weight (g)	36.43	34.32	34.88
Sex ratio	1.75	1	-
Length at first maturity (cm)	11.8	11.8	-

110 samples exhibited mature gonads, comprising mature males (n=70) and mature females (n=40). The remaining 10 individuals possessed immature or undifferentiated gonads and were therefore considered unsexed. Mature individuals predominantly fell within the 10–15 cm total length (TL) range, whereas immature or unsexed individuals were generally <10 cm TL. Among the mature specimens, 4 individuals (10–12 cm TL) exhibited intersex gonadal characteristics. This observation suggests a potentially significant incidence of gonadal intersexuality within this population, warranting further investigation into developmental and environmental factors contributing to this condition.

The gross and histological characteristics of the mid-region of the testis in *A. vaigiensis* are illustrated in Fig. 2. The ripe testis (Fig. 2a) was compact, whitish, and bilobed, with notable asymmetry; the right lobe being more elongated. This morphology aligns with descriptions of mature male gonads in many perciform teleosts (West, 1990; Nagahama, 1983).

Histological analysis (Fig. 2b) revealed well-organised seminiferous lobules containing spermatocytes, spermatids, and abundant spermatozoa, confirming active spermatogenesis. The presence of a well-defined lumen filled with spermatozoa is indicative of full gonadal maturation (Billard, 1986; Grier, 1981). The arrangement of spermatogenic cysts along the lobules reflects the cystic mode of spermatogenesis typical of teleosts with tubular testes (Grier, 1993). These features support the classification of *A. vaigiensis* as a gonochoristic species, with mature individuals exhibiting typical male reproductive anatomy and no histological evidence of intersexuality. This is consistent with previous reports on reproductive

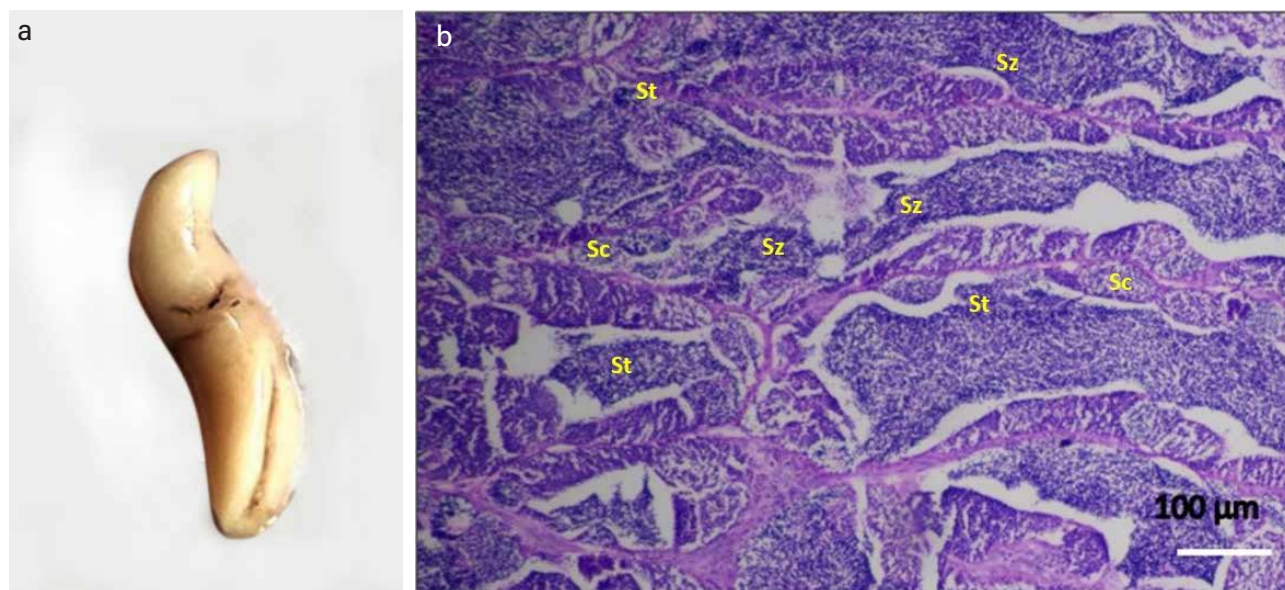


Fig. 2. Gross morphology of mature testis, a) and the histological details, b) of the mid portion of the testis with elongated testicular lobules having spermatozoa (Sz); spermatocytes (Sc), spermatids (St) (dark purple dotted structures)

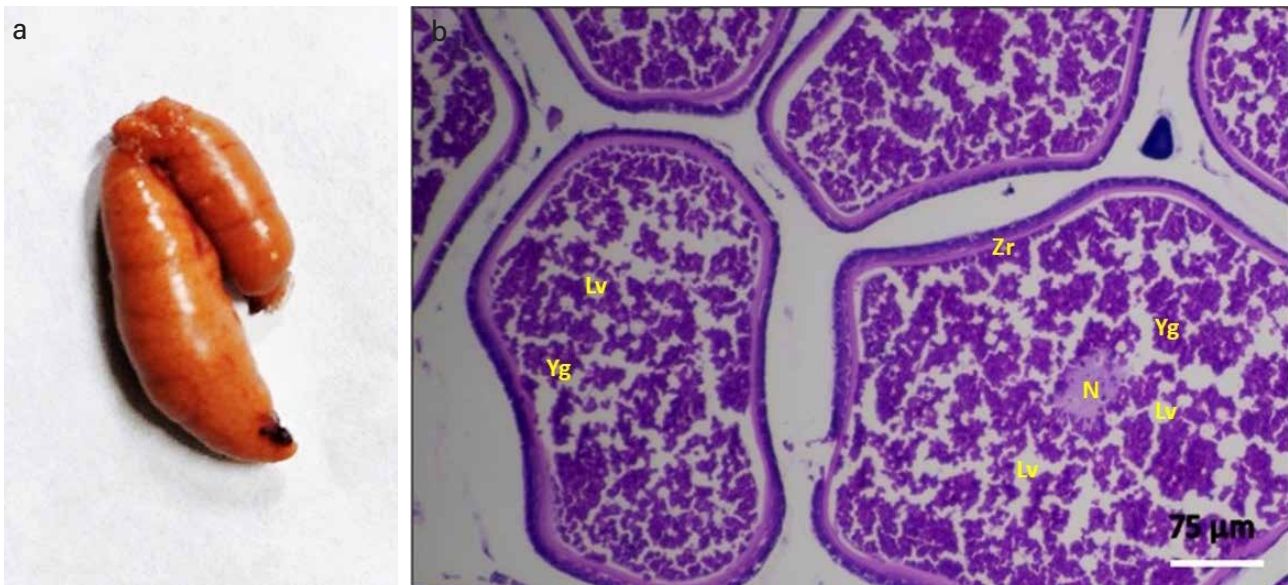


Fig. 3. Gross morphology of a mature ovary, a) and the histological details, b) of the mid portion of the ovary with mature oocytes. N- nucleus; Lv – lipid vesicles; Zn – zona radiata; Yg –yolk granules

strategies in *Abudefduf* spp. though seasonal and size-related variation should be further investigated to explore potential reproductive plasticity.

The gross morphology and histological features of the mid-region of the ovary are shown in Fig. 3. The mature ovary (Fig. 3a) appeared cylindrical and dark orange, with prominent vitellogenic oocytes visible on the surface. Asymmetry in ovarian lobe length was observed, similar to patterns seen in other marine teleosts (West, 1990). Histological sections (Fig. 3b) showed numerous large vitellogenic oocytes containing well-developed yolk granules and a distinct zona radiata, indicating readiness for spawning (Wallace and Selman, 1981). Additionally, the presence of perinuclear and cortical alveolar stage oocytes suggests asynchronous ovarian development, a feature associated with prolonged or batch spawning in teleost fishes (Tyler and Sumpter, 1996; Murua and Saborido-Rey, 2003). The absence of any testicular tissue at both gross and histological levels further supports the gonochoristic nature of these individuals. However, the detection of asynchronous oogenesis may reflect adaptive reproductive traits commonly observed in damselfishes (Sadovy and Shapiro, 1987).

The gross and histological examination of a gonad revealed characteristics consistent with a functional ovotestis (Fig. 4), revealing the intersex condition. Grossly, the gonad was bipartite, with a regressed testicular lobe and a prominent ovarian lobe (Fig. 4a). Histological analysis (Fig. 4b–d) confirmed the presence of spermatogenic tissue, characterized by germinal cells (spermatogonia and spermatocytes), and

proliferation of interstitial connective tissue, coexisting with early-stage oocytes (chromatin nucleolar and perinucleolar stages) in the ovarian lobe.

These findings are indicative of testicular tissue in the developing ovary, consistent with either a protandrous sex change (Sadovy and Shapiro, 1987; Devlin and Nagahama, 2002; Munday *et al.*, 2006) or due to endocrine disruption. A notable example is the feminisation of wild male roach (*Rutilus rutilus*) in UK rivers receiving treated sewage effluent, linked

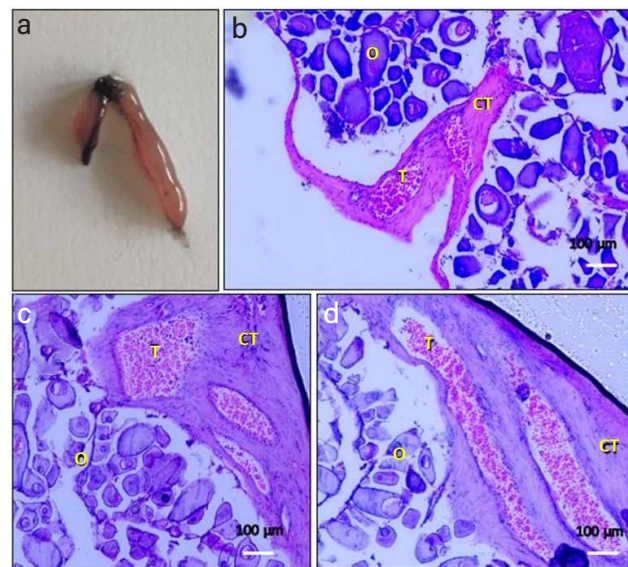


Fig. 4. Gross morphology of ovo-testis, a) and histology of inter sex gonad, b-d) showing testicular tissue (T) distributed in maturing ovary having developing oocytes (O). The gonad was characterized by the large mass of connective tissue (CT)

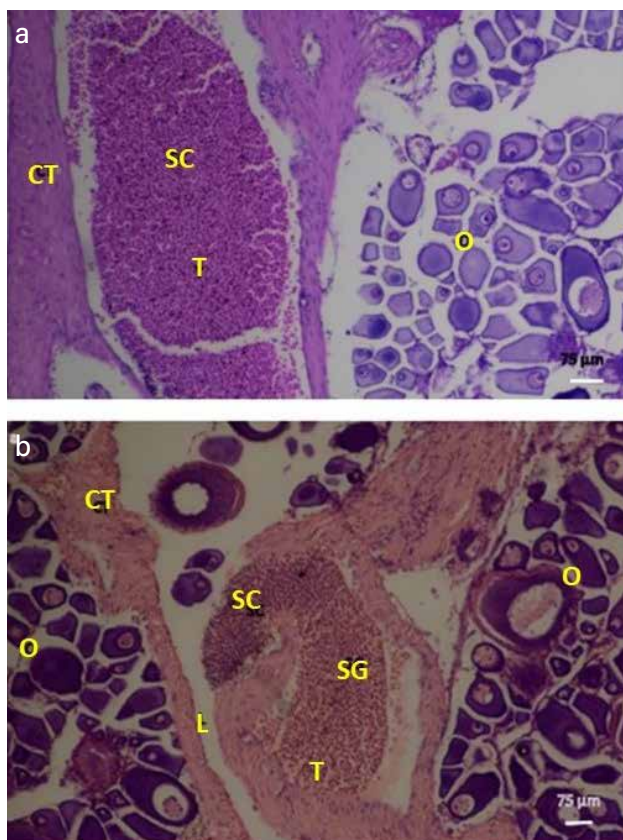


Fig. 5. Histology of intersex gonad showing testicular tissue: a) periphery of the ovary, b) lumen of the ovary. Notations: T –testicular portion, O - maturing ovary, CT -connective tissue, L – lumen; SC – spermatocytes, SG – spermatogonia

to elevated levels of synthetic estrogens (Jobling *et al.*, 1998). Another striking case involves whole-lake experiments in Canada, where chronic exposure to ethinylestradiol led to population collapse of fathead minnows (*Pimephales promelas*) (Kidd *et al.*, 2007). Minmol *et al.* (2017) reported the presence of organochlorine (a potential endocrine disruptor) pesticide residues in seaweeds from Mandapam coast, India. However, there have been reports of intersex at reference sites free of environmental influences (Hecker *et al.*, 2002; Marchand *et al.*, 2010; Bahamonde *et al.*, 2013). While hermaphroditism is well-documented in related reef fish families such as Labridae and Serranidae, it has not been previously reported in *Abudefduf* spp., which are generally considered gonochoristic. *A. vaigiensis* is a gonochoristic ornamental reef fish without sexual dimorphism (Canini and Metello, 2024).

The family Pomacentridae is well known for its wide array of reproductive strategies, encompassing gonochorism with genetically predetermined sex, as well as various forms of hermaphroditism. These include protogyny, protandry, and bisexuality marked by gonadal primordia containing both male and female germ cells (Fishelson, 1998). Within this family, evidence for protogynous hermaphroditism has been

documented in *Dascyllus reticulatus*, where initial observations by Schwarz and Smith (1990) were later corroborated by Schwarz (1995). In contrast, non-functional protogynous development has been described in *Dascyllus albisella*. Asoh *et al.* (2001) reported that although ovarian development initiates along a protogynous pathway, sex transition to male occurs before completion of vitellogenesis, typically between the cortical alveolus stage and final oocyte maturation, before spawning.

The present observation of an ovotestis in *A. vaigiensis* represents the first histological evidence suggesting the potential for sequential hermaphroditism in this species. These finding challenges traditional views on the reproductive strategy of *Abudefduf* and underscore the need for broader sampling across size classes, seasons, and populations to assess the extent and ecological significance of sexual plasticity in this taxon.

While the present study primarily aimed to document the occurrence of intersex conditions and their associated morphological features, we recognise that identifying the specific causative agents would provide a more robust understanding of the phenomenon. Accordingly, we have expanded the Future Research Directions section to emphasise the critical need for comprehensive environmental contaminant screening in this region. This includes targeted analyses of estrogenic compounds, industrial pollutants such as polychlorinated biphenyls (PCBs) and polycyclic aromatic hydrocarbons (PAHs), agricultural runoff containing pesticides and herbicides, pharmaceutical residues, as well as relevant abiotic stressors. Such integrative investigations are essential to elucidate the potential etiological links between environmental exposure and endocrine disruption in local fish populations.

## Conclusion

The study provides insights into the gonadal morphology and reproductive strategy of *A. vaigiensis*. Gross and histological examinations confirmed the presence of distinct testes and ovaries in mature individuals, supporting the species' gonochoristic classification. However, the discovery of a transitional gonad exhibiting both regressed testicular and developing ovarian tissue presents the first histological evidence of sequential hermaphroditism in this species. This unexpected finding suggests the potential for protandrous sex change in *A. vaigiensis*. Further research involving extensive temporal, spatial, and size-based sampling is essential to determine the prevalence and ecological significance of sexual plasticity in this taxon.

## Acknowledgements

The authors are indebted to the Director, ICAR-Central Marine

Fisheries Research Institute, Kochi, for the valuable inputs and guidance received for the research. The study is part of the Institutional project (MDN/HCY/18) of ICAR-Central Marine Fisheries Research Institute, Kochi.

### Author contributions

Conceptualisation: NR; Methodology: MTS, AA, PS; Data collection: NR, KKA; Data Analysis: NR, PPSB; Writing Original Draft: NR, PPSB; Writing review and editing: NR, PPSB, Supervision: BI

### Data availability

The data are available and can be requested from the corresponding author.

### Conflict of interest

The authors declare that they have no conflict of financial or non-financial interests that could have influenced the outcome or interpretation of the results.

### Ethical statement

This study was conducted following ethical guidelines for research on food fishes in India, as outlined by the CPCSEA.

### Funding

This research was supported by ICAR-Central Marine Fisheries Research Institute, Kochi, through its institutional research project 'Development of hatchery technologies for commercially important species in mariculture' (Project code: MDN/HYD/18).

### Publisher's note

The views and claims presented in this article are solely those of the authors and do not necessarily reflect the positions of the publisher, editors, or reviewers. The publisher does not endorse or guarantee any claims made by the authors or those citing this article.

## Reference

- Allen, G. R. 1975. Damsel fishes of South Seas. TFH Publications International, New Jersey, 240 pp.
- Asoh, K., T. Yoshikawa, R. K. Kosaki and A. Nakazono. 2001. Gonadal development and population structure of the damselfish *Dascyllus albisella*: evidence for non-functional protogyny. *Environ. Biol. Fishes*, 61 (2): 135-144.
- Bahamonde, P. A., K. R. Munkittrick and C. J. Martyniuk. 2013. Intersex in teleost fish: are we distinguishing endocrine disruption from natural phenomena? *Gen. Comp. Endocrinol.*, 192: 25-35.
- Billard, R. 1986. Spermatogenesis and spermatology of some teleost fish species. *Reproduction Nutrition Development*, 26 (4): 877-920.
- Canini, N. D. and E. B. Metillo. 2024. Reproductive Biology of the Aquarium Marine Fish *Abudefduf vaigiensis* (Quoy & Gaimard, 1825) from Iligan Bay, Southern Philippines. *The Philippine Journal of Fisheries*, 31 (2): 305-320.
- Devlin, R. H., and Nagahama, Y. 2002. Sex determination and sex differentiation in fish: An overview of genetic, physiological, and environmental influences. *Aquaculture*, 208 (3-4), 191-364.
- Fishelson, L. 1998. Experiments and observations on sex reversal in Anthiine fishes (Serranidae) in the Gulf of Aqaba, Red Sea. *Isr. J. Zool.*, 44 (1): 29-35.
- Gabe, M. 1976. Histological Techniques. R E Blackith, translator. Springer-Verlag, New York Inc., New York, p. 298-300.
- Grier, H. J. 1981. Cellular organization of the testis and spermatogenesis in fishes. *Am. Zool.*, 21 (2): 345-357.
- Grier, H. J. 1993. Comparative organization of Sertoli cells including the Sertoli cell barrier. In: Russell, L. D. and Griswold, M. D. (Eds.). *The Sertoli Cell*, Clearwater, FL: Cache River Press, p. 704-739.
- Hinck, J. E., V. S. Blazer, C. J. Schmitt, D. M. Papoulias and D. E. Tillitt. 2009. Widespread occurrence of intersex in black basses (*Micropterus* spp.) from US rivers, 1995-2004. *Aquat. Toxicol.*, 95 (1): 60-70.
- Hecker, M., C. R. Tyler, M. Hoffmann, S. Maddix and L. Karbe. 2002. Plasma biomarkers in fish provide evidence for endocrine modulation in the Elbe River, Germany. *Environ. Sci. Technol.*, 36 (11): 2311-2321.
- Jobling, S., M. Nolan, C. R. Tyler, G. Brighty and J. P. Sumpter. 1998. Widespread sexual disruption in wild fish. *Environmental Science and Technology*, 32 (17): 2498-2506.
- Kidd, K. A., P. J. Blanchfield, K. H. Mills, V. P. Palace, R. E. Evans, J. M. Lazorchak and R. W. Flick. 2007. Collapse of a fish population after exposure to a synthetic estrogen. *Proc. Natl. Acad. Sci.*, 104 (21): 8897-8901.
- Marchand, M. J., G. M. Pieterse and I. E. J. Barnhoorn. 2010. Sperm motility and testicular histology as reproductive indicators of fish health of two feral fish species from a currently DDT sprayed area, South Africa. *J. Appl. Ichthyol.*, 26 (5): 707-714.
- Minimol, V. A., K. K. Anas, R. Anandan and S. Mathew. 2017. Monitoring organochlorine pesticide residues in seaweeds from Mandapam coast, India. *Fish Tech Rep.*, 3 (2): 7-9.
- Munday, P. L., P. M. Buston and R. R. Warner. 2006. Diversity and flexibility of sex-change strategies in animals. *Trends Ecol. Evol.*, 21 (2): 89-95.
- Murua, H. and F. Saborido-Rey. 2003. Female reproductive strategies of marine fish species of the North Atlantic. *Journal of Northwest Atlantic Fishery Science*, 33: 23-31.
- Mylonas, C. C., A. Fostier and S. Zanuy. 2010. Broodstock management and hormonal manipulations of fish reproduction. *Gen. Comp. Endocr.*, 165 (3): 516-534.
- Nagahama, Y. 1983. The functional morphology of teleost gonads. In: Hoar, W. S., Randall, D. J., and Donaldson, E. M. (Eds.) *Fish Physiology*, Vol. 9, Reproduction, Academic Press, p. 223-275.
- Randall, J. E. 2005. Reef and Shore Fishes of the South Pacific. Honolulu, HI, University of Hawaii Press, Hawaii, USA. 254 pp.
- Sadovy, Y. and Shapiro, D. Y. 1987. Criteria for the diagnosis of hermaphroditism in fishes. *Copeia*, 1987 (1): 136-156.
- Schreck, C. B. 2010. Stress and fish reproduction: The roles of allostatics and hormesis. *General and Comparative Endocrinology*, 165 (3): 549-556.
- Schwarz, A. L. 1995. Evidence of protogynous hermaphroditism in *Dascyllus reticulatus* (Pomacentridae). *Environ. Biol. Fishes*, 42 (3): 251-255.
- Schwarz, A. L. and L. C. Smith. 1990. Sex change in the damselfish *Dascyllus reticulatus*. *Copeia*, 1990 (4): 1098-1103.
- Tyler, C. R. and J. P. Sumpter. 1996. Oocyte growth and development in teleosts. *Rev. in Fish Biol. Fish.*, 6 (3): 287-318.
- Tyler, C. R. and S. Jobling. 2008. Roach, sex, and gender-bending chemicals: the feminization of wild fish in English Rivers. *Bioscience* 58: 1051-1059.
- Wabnitz, C., M. Taylor, E. Green and T. Razak. 2003. From Ocean to Aquarium. The global trade in marine ornamental species. Cambridge, UK: UNEP-WCMC. 64 pp.
- Wallace, R. A. and K. Selman. 1981. Cellular and dynamic aspects of oocyte growth in teleosts. *Am. Zool.*, 21 (2): 325-343.
- Warner, R. R. 1984. Mating behaviour and hermaphroditism in coral reef fishes: the diverse forms of sexuality found among tropical marine fishes can be viewed as adaptations to their equally diverse mating systems. *Am. Sci.*, 72 (2): 128-136.
- West, G. 1990. Methods of assessing ovarian and testicular development in fishes: A review. *Aust. J. Mar. Freshwater Res.*, 41 (2): 199-22